

# 先天性筋膜失養：僵直皮膚徵候群之一種變異型

許致榮 蕭正祥\* 張俊祥 王莉芳

台大醫院皮膚部 病理部\*

## Congenital Fascial Dystrophy: A Variant of Stiff Skin Syndrome

Chih-Jung Hsu Cheng-Hsiang Hsiao\* Chun-Hsiang Chang Li-Fang Wang

Congenital fascial dystrophy (a variant of stiff skin syndrome) is a rare scleroderma-like genetic disorder characterized by stony-hard skin, limited joint mobility and flexural contracture of the limbs. The onset is at birth, and the disease occurs without sclerodactyly, telangiectases, nail fold changes and visceral involvement. We report a typical case to illustrate the clinical and pathologic findings of a patient with this disorder. To our knowledge, this is the first case of this disorder in Taiwan to be reported. (*Dermatol Sinica* 20 : 223-228, 2002)

*Key words:* Congenital fascial dystrophy, Stiff skin syndrome, Scleroderma.

先天性筋膜失養(屬於僵直皮膚徵候群之一種變異型)是一種罕見的、鞏皮樣、基因性皮膚疾患，其臨床特徵為石頭般的硬皮，關節活動之限制，以及肢體之屈側攣縮。然而，不同於鞏皮症的是，此病多在出生時便發病，且不伴隨肢端硬化，微血管擴張，指甲病變及內臟變化。本篇報告一個典型之病例並詳述其臨床及病理之變化。就我們知識所及，此為台灣第一個被報告之病例個案。(中華皮誌20：223-228, 2002)

### INTRODUCTION

In 1971, Esterly and McKusick<sup>1</sup> described four patients with localized areas of stony-hard skin, limited joint mobility, and mild hirsutism. These patients had no other abnormalities and no increased excretion of mucopolysaccharides in the urine. Because this disorder did not correspond to any known collagen disease or

mucopolysaccharidosis, Esterly and McKusick called it "stiff skin syndrome." Later, Jablonska *et al.*<sup>2</sup> described four patients with a similar disorder and found that these patients had a unique abnormality-fascia three to four times the normal thickness. Since some of these cases were genetically determined, these investigators proposed the name "congenital fascial

*From the Departments of Dermatology and Pathology\* National Taiwan University Hospital*

*Accept for publication: January 31, 2002*

*Reprint requests: Chih-Jung Hsu, M.D., Department of Dermatology, National Taiwan University Hospital, No. 7, Chung-Shan South Road, Taipei 100, Taiwan TEL: 02-23562141 FAX: 02-23934177 E-mail: cz038@ms29.hinet.net*

dystrophy" for this variant of stiff skin syndrome. Here, we present a case of congenital fascial dystrophy and discuss our clinical, pathological, and electron microscopic findings. Because the prognosis is dramatically different from scleroderma, awareness of this disorder will enable the physician to make a rapid diagnosis and to avoid any unnecessary therapy.

## CASE REPORT

This 5-year-old boy was born without obvious congenital anomaly except mild hypertrichosis over his left lateral thigh. Nobody in his family had a similar disease. When he was 3-year-old, skin hardness of the left lateral thigh under the hypertrichosis zone was found accidentally by his baby sitter. He was brought to a local hospital, where soft tissue echo and x-ray were performed. The result of x-ray was normal. No definite diagnosis except "hyperplasia of fascia" was demonstrated from the echo result.

Unfortunately, the areas of skin hardness extended slowly and progressively. Gradually, his left buttock was also involved, which mildly limited the motion of his left hip joint. We saw him first at the age 3.5 years. The color and texture of the patient's skin looked grossly normal. However, when palpated, his lateral thigh had an ill-defined indurated band with hypertrichosis of the overlying skin. The skin was relatively immovable and difficult to pinch out. Under the impression of linear morphea, biopsy with depth to superficial subcutis was performed. Pathological examination revealed mild dermal fibrosis with scanty inflammatory cells only. Appendage atrophy or homogenization of collagen was not seen. Other laboratory data, including assays of ANA, anti-ENA, C3, C4, and C-reactive protein, were normal. He was then treated with azathioprine (25 mg/day) and hydroxychloroquine (100 mg/day) for six months. However, the stony-hard skin persisted without improvement (Fig. 1) and another two similar hardness skin bands over left and right medial thigh developed subsequently.

One year later, he was admitted for further examination. His laboratory examination was repeated and all parameters were still normal. Urine mucopolysaccharide was also checked. Although the level was slight higher than normal, it was still far from the criterion defining mucopolysaccharidosis. Musculoskeletal echo was arranged and revealed a near 2-fold increase in thickness of the fascia in the induration area of the left thigh (Fig. 2). No myopathic change was noted from EMG study. Under the suspicion of stiff-skin syndrome, a second biopsy was cut deep to the fascia to obtain enough tissue for diagnosis.

Microscopically, the change in the dermis was still found to be nonspecific, as in the previous biopsy. The eccrine glands were preserved and there was no "bound-down" phenomenon. The most dramatic change was the prominently increased thickness in the interlobular septum of subcutaneous tissue, and in particular, in the fascia. (Fig. 3) There was no remarkable inflammatory infiltrates in the subcutaneous tissue and fascia. The thickened fascia was composed of thick hyalinized collagenous bundles which contained scanty fibroblasts and looked like degenerated muscle bundles. However, Masson trichome stain proved these bundles to be collagen rather than muscle. (Fig. 4) Alcian blue stain showed no increased mucopolysaccharide in the dermis. The muscle was normal. By electron microscopy study, aggregates of giant fibrils could be identified between the native collagen fibrils. Some giant fibrils showed divisions into 2 or 3 fibrils, which could suggest that giant fibrils derived from fusion of more slender fibrils. Besides this, many curved, V-shaped fibrils were found, which is not the normal components of collagen fiber. On cross sections, the profiles of collagen fibril were circular and irregular in their sizes (Fig. 5).

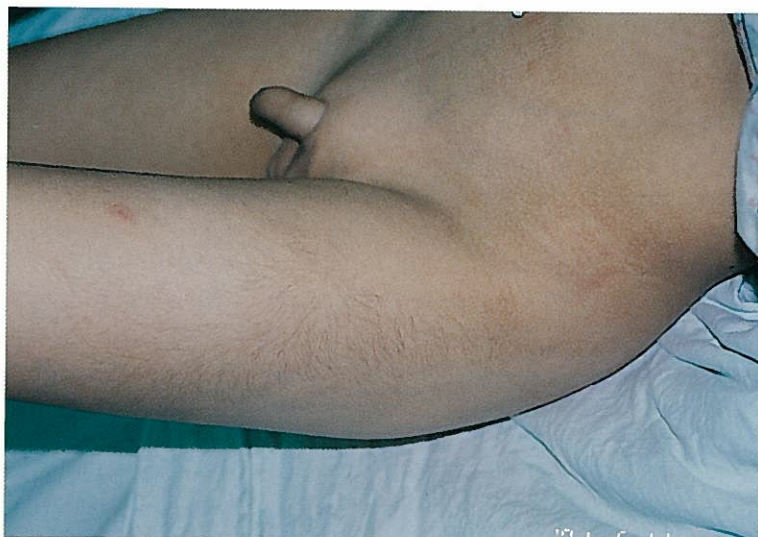From the clinical, pathological, and laboratory results, we made the diagnosis of congenital fascial dystrophy (stiff skin syndrome). Immunosuppressive therapy was then

discontinued and rehabilitation for improving joint motion was suggested. After seven-months course of rehabilitation, the boy showed no progression his disease condition and improved greatly in range of movement.

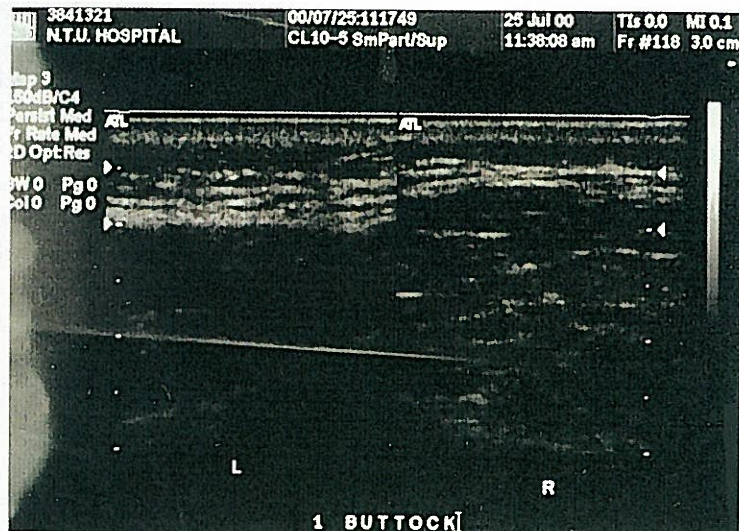
### DISCUSSION

In 1971, Esterly and McKusick characterized stiff skin syndrome (SSS), a rare genetic disorder, by stony-hard indurations of the skin and deeper tissues, limitation of joint mobility and mild hypertrichosis.<sup>1</sup> In their

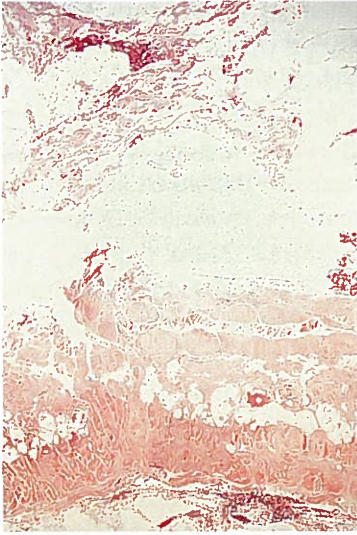
original report, it was attributed to a noninflammatory dermal fibrosis with homogenization of the connective stroma due to abnormal mucopolysaccharide metabolism limited to skin. However, these features were not consistently found in reports that followed.<sup>3,4</sup> Kikuchi *et al.*<sup>5</sup> suggested that there were two varieties of the SSS: one with increased acid mucopolysaccharides in the dermis in the absence of mucopolysacchariduria and another variety, congenital fascial dystrophy (CFD), with increased accumulation of collagen in fascia.



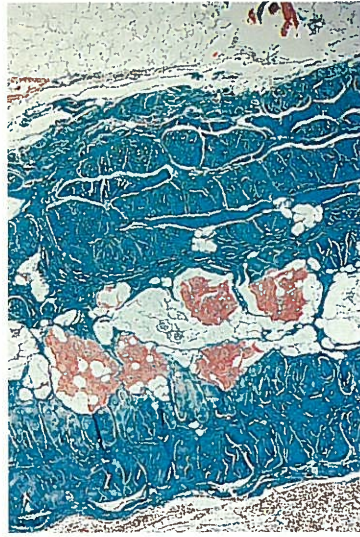
**Fig. 1**  
Ill-defined indurated skin with hypertrichosis of the overlying skin.



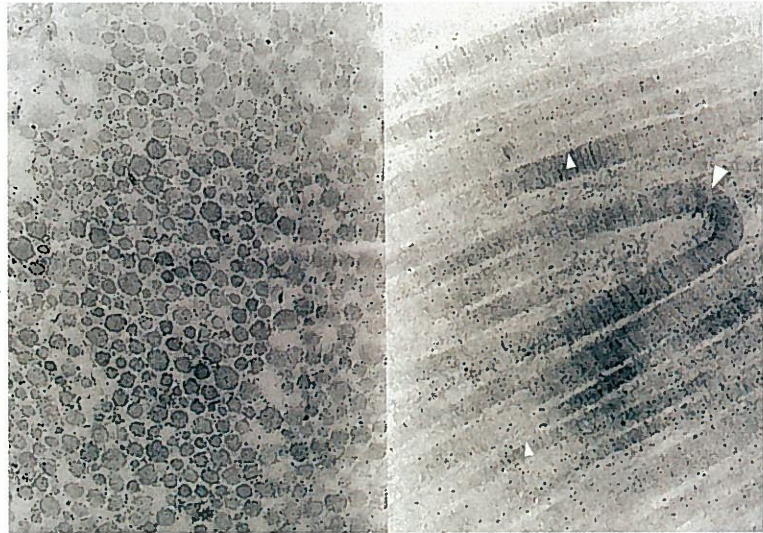
**Fig. 2**  
Sonogram shows increased thickness of the fascia in left thigh, compared with right thigh.



**Fig. 3**  
No remarkable inflammatory infiltrates in the thickened fascia. (x20)



**Fig. 4**  
Masson-trichrome stain highlights the thickened fascia originated from collagen fibers. (x40)



**Fig. 5**  
left: On cross sections, the profiles of collagen fibril are circular and in various sizes (original magnification, x30000)  
Right: One V-shaped fibril (large pointer) was found in the aggregated giant branched fibrils (small pointers) (original magnification, x50000)

Nevertheless, all patients of SSS, including two varieties, have the following characteristics.<sup>2,3,6-8</sup>

- \* Early onset: usually at infancy or early childhood, but sometimes noted at birth
- \* Characteristic distribution: the subcutaneous indurations usually first appears on the buttocks and thighs, which are also sites of the

most pronounced involvement. Gradually, induration may extend slowly to lower back, knees and legs with contracture of the knees and hip joints. To a lesser degree, the stony-hard skin may form on the shoulders and arms. If this happens, progressive constriction of thorax may result in pulmonary restrictive changes. The

changes. The distal parts of the limbs are usually less involved, and the hands and feet are spared.

- \* Slowly progressive course: at first, it was thought of as nonprogressive disorder. However, during long-term follow-up, some cases run a slowly progressive course. In patients with extensive involvement, short stature with typical tip-toe posture and a peculiar mode of walking may be observed.
- \* Visceral, musculoskeletal, vascular or immunologic abnormalities are absent, and urine mucopolysaccharides are not increased.
- \* Possible pulmonary restrictive changes: the only severe complication is due to progressive constriction of the thorax with age.
- \* No histologic signs of inflammation in the skin, subcutis, fascia and muscles are seen.
- \* In electron microscopy of the fascia, amiantoid-like collagen fibers-giant fibrils with some of them showing divisions into two or three fibrils are seen.

Our case had all the characteristics mentioned above, except pulmonary restrictive changes. We didn't check it due to the lack of involvement in the upper trunk and limbs. In addition, we observed an unusual findings in electron microscopic examination, V-shaped fibril, which have not been mentioned in previous reports. The differential diagnosis of CFD should include disorders with skin stiffness. Sclerema neonatorum can be easily excluded by the absence of prematurity and lack of associated underlying diseases in the clinical history.<sup>9</sup> CFD can be differentiated from systemic sclerosis because Raynaud's phenomenon, visceral involvement and immunological abnormalities are all absent.<sup>2,9</sup> CFD also differs from linear morphea because the latter involve not only skin and subcutaneous tissues, but also muscles and bones. Besides, linear morphea usually appears later (at 7-8 years of age) and shows atrophic epidermis and decreased or absent skin appendages.<sup>7</sup> CFD and eosinophilic fasciitis shared the same figure that both disorder revealed increased thickness in fascia and replacement of the subcutis by collagenous

replacement of the subcutis by collagenous tissue. However, the age of onset and clinical course were different. The lack of inflammation cells in fascia and the thickened homogenized collagen bundle instead of sclerotic fibrosis differentiated CFD from eosinophilic fasciitis in histopathology. Atypical CFD may be difficult to differentiate from morphea profunda. However, in our case, the slowly progressive course, the absent to minimal inflammation found in the biopsy specimen, and the prominent fascial thickening favor the CFD diagnosis.

The pathogenesis of congenital fascial dystrophy is unclear. Previous study disclosed increased collagen synthesis by fibroblasts derived from the deeper portions of the skin, a high rate of total collagen synthesis per cell, and a high ratio of collagen synthesis to total protein synthesis.<sup>2</sup> Although there is almost no inflammation in the biopsied lesional skin, serum levels of some proinflammatory cytokines, including tumor necrosis factor -  $\alpha$ , interleukin-6 and transforming growth factor- $\beta$  2, had been found to be high in a case of familial stiff skin syndrome.<sup>9</sup> So, whether the imbalance in collagen synthesis is genetically programmed or related to subtle chronic inflammation, still needs clarification by further studies.

There are still no known effective treatments for this disorder. However, we can be reassured that this disorder has a non- or only slowly progressive course, without impairment of the general condition.<sup>7</sup> Only rehabilitation exercises are indicated, especially for prevention of contractures and restrictive pulmonary changes which may appear at an older age. The patients have a favorable prognosis if rehabilitation starts at an early age and is continued throughout life.<sup>7</sup> Recently, several agents were found to have antifibrotic property, such as Cu-Zn SOD<sup>10</sup>, minoxidil<sup>11</sup>, and ethyl 3,4-dihydroxybenzoate.<sup>12</sup> Although these agents were still in laboratory stage, they may provide a more direct treatment for these patients in the future.

## REFERENCES

1. Esterly NB, McKusick VA: Stiff skin syndrome. *Pediatrics* 47: 360-369, 1971.
2. Jablonska S, Schubert H, Kikuchi I: Congenital fascial dystrophy: stiff skin syndrome--a human counterpart of the tight-skin mouse. *J Am Acad Dermatol* 21: 943-950, 1989.
3. Helm TN, Wirth PB, Helm KF: Congenital fascial dystrophy: the stiff skin syndrome. *Cutis* 60: 153-154, 1997.
4. Bundy SE, Lie K: Stiff skin syndrome. *Birth Defects Orig Artic Ser* 11: 360-361, 1975.
5. Kikuchi I, Inoue S, Hamada *et al.*: Stiff skin syndrome. *Pediatr Dermatol* 3: 48-53, 1985.
6. Fidzianska A, Jablonska S: Congenital fascial dystrophy: abnormal composition of the fascia. *J Am Acad Dermatol* 43: 797-802, 2000.
7. Jablonska S, Blaszczyk M: Scleroderma-like indurations involving fascias: an abortive form of congenital fascial dystrophy (Stiff skin syndrome). *Pediatr Dermatol* 17: 105-110, 2000.
8. Gilaberte Y, Saenz-de-Santamaria MC, Garcia-Latasa FJ *et al.*: Stiff skin syndrome: a case report and review of the literature. *Dermatology* 190: 148-151, 1995.
9. Richard MA, Grob JJ, Philip N *et al.*: Physiopathogenic investigations in a case of familial stiff-skin syndrome. *Dermatology* 197: 127-131, 1998.
10. Vozenin-Brotans MC, Sivan V, Gault N *et al.*: Antifibrotic action of Cu/Zn SOD is mediated by TGF-beta1 repression and phenotypic reversion of myofibroblasts. *Free Radic Biol Med* 30: 30-42, 2001.
11. Parish JL, Hughes MA, Cherry GW *et al.*: The effect of minoxidil analogues and metabolites on the contraction of collagen lattices by human skin fibroblasts. *Br J Plast Surg* 48: 154-160, 1995.
12. Majamaa K, Sasaki T, Uitto J: Inhibition of prolyl hydroxylation during collagen biosynthesis in human skin fibroblast cultures by ethyl 3,4-dihydroxybenzoate. *J Invest Dermatol* 89: 405-409, 1987.